

611/084.4  
A 64

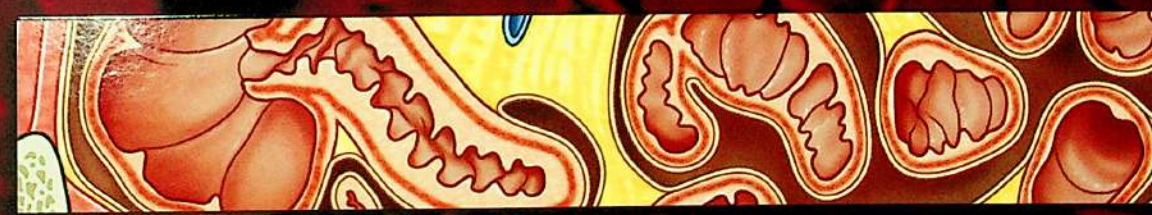Study smart with

Student Consult

# GRAY'S

# ATLAS OF ANATOMY

SECOND EDITION



Richard L. Drake    A. Wayne Vogl    Adam W. M. Mitchell  
Richard M. Tibbitts    Paul E. Richardson

ELSEVIER

611(084.4)  
A64

CHURCHILL  
LIVINGSTONE  
ELSEVIER

1600 John F. Kennedy Blvd.  
Ste 1800  
Philadelphia, PA 19103-2899



GRAY'S ATLAS OF ANATOMY, SECOND EDITION  
INTERNATIONAL EDITION

ISBN: 978-1-4557-4802-0  
ISBN: 978-0-7020-5237-8

Copyright © 2015, 2008 by Churchill Livingstone, an imprint of Elsevier Inc.

**All rights reserved.** No part of this publication may be reproduced or transmitted in any form or by any means, electronic or mechanical, including photocopying, recording, or any information storage and retrieval system, without permission in writing from the publisher. Details on how to seek permission, further information about the Publisher's permissions policies and our arrangements with organizations such as the Copyright Clearance Center and the Copyright Licensing Agency, can be found at our website: [www.elsevier.com/permissions](http://www.elsevier.com/permissions).

#### Notices

Knowledge and best practice in this field are constantly changing. As new research and experience broaden our understanding, changes in research methods, professional practices, or medical treatment may become necessary.

Practitioners and researchers must always rely on their own experience and knowledge in evaluating and using any information, methods, compounds, or experiments described herein. In using such information or methods they should be mindful of their own safety and the safety of others, including parties for whom they have a professional responsibility.

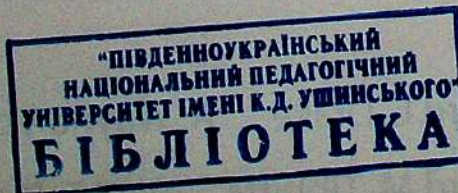
With respect to any drug or pharmaceutical products identified, readers are advised to check the most current information provided (i) on procedures featured or (ii) by the manufacturer of each product to be administered, to verify the recommended dose or formula, the method and duration of administration, and contraindications. It is the responsibility of practitioners, relying on their own experience and knowledge of their patients, to make diagnoses, to determine dosages and the best treatment for each individual patient, and to take all appropriate safety precautions.

To the fullest extent of the law, neither the Publisher nor the authors, contributors, or editors, assume any liability for any injury and/or damage to persons or property as a matter of products liability, negligence or otherwise, or from any use or operation of any methods, products, instructions, or ideas contained in the material herein.

The Publisher

ISBN: 978-1-4557-4802-0

544291



VP Global Medical Education Content: Madelene Hyde  
Senior Manager, Content Development: Rebecca Grulio  
Publishing Services Manager: Patricia Tannian  
Senior Project Manager: John Casey  
Design and Art Direction: Antbits Ltd.

Working together to grow  
libraries in developing countries  
[www.elsevier.com](http://www.elsevier.com) | [www.bookaid.org](http://www.bookaid.org) | [www.sabre.org](http://www.sabre.org)  
ELSEVIER BOOKAID Since 1983

Printed in Canada  
Last digit is the print number: 9 8 7 6 5 4 3 2

**1 THE BODY**

<i>Anatomical position, terms, and planes</i>	2
<i>Anatomical planes and imaging</i>	3
<i>Surface anatomy: anterior view</i>	4
<i>Surface anatomy: posterior view</i>	5
<i>Skeleton: anterior</i>	6
<i>Skeleton: posterior</i>	7
<i>Muscles: anterior</i>	8
<i>Muscles: posterior</i>	9
<i>Vascular system: arteries</i>	10
<i>Vascular system: veins</i>	11
<i>Lymphatic system</i>	12
<i>Nervous system</i>	13
<i>Sympathetics</i>	14
<i>Parasympathetics</i>	15
<i>Dermatomes</i>	16
<i>Cutaneous nerves</i>	17

**2 BACK**

<i>Surface anatomy</i>	20
<i>Vertebral column</i>	21
<i>Regional vertebrae</i>	22
<i>Cervical vertebrae</i>	23
<i>Thoracic vertebrae</i>	26
<i>Lumbar vertebrae</i>	28
<i>Sacrum</i>	31
<i>Intervertebral foramina and discs</i>	32
<i>Intervertebral disc problems</i>	33
<i>Joints and ligaments</i>	35
<i>Back musculature: surface anatomy</i>	36
<i>Superficial musculature</i>	37
<i>Intermediate musculature</i>	39
<i>Deep musculature</i>	40
<i>Back musculature: transverse section</i>	42
<i>Suboccipital region</i>	43
<i>Spinal nerves</i>	44
<i>Spinal cord</i>	45
<i>Spinal cord vasculature</i>	46
<i>Venous drainage of spinal cord</i>	47

<i>Meninges</i>	48
<i>Spinal cord: imaging</i>	50
<i>Transverse section: thoracic region</i>	52
<i>Dermatomes and cutaneous nerves</i>	53
<i>Tables</i>	54

**3 THORAX**

<i>Surface anatomy with bones</i>	62
<i>Bony framework</i>	63
<i>Ribs</i>	65
<i>Articulations</i>	66
<i>Breast</i>	68
<i>Pectoral region</i>	70
<i>Thoracic wall muscles</i>	72
<i>Diaphragm</i>	73
<i>Arteries of the thoracic wall</i>	74
<i>Veins of the thoracic wall</i>	75
<i>Nerves of the thoracic wall</i>	76
<i>Lymphatics of the thoracic wall</i>	77
<i>Intercostal nerves and arteries</i>	78
<i>Pleural cavities and mediastinum</i>	79
<i>Parietal pleura</i>	80
<i>Surface projections of pleural recesses</i>	81
<i>Right lung</i>	82
<i>Left lung</i>	83
<i>Lung lobes: surface relationship</i>	84
<i>Lung lobes: imaging</i>	85
<i>Bronchial tree</i>	86
<i>Bronchopulmonary segments</i>	87
<i>Pulmonary vessels and plexus</i>	88
<i>Pulmonary vessels: imaging</i>	89
<i>Mediastinum</i>	91
<i>Pericardium</i>	92
<i>Pericardial layers</i>	93
<i>Anterior surface of heart</i>	94
<i>Base and diaphragmatic surface of heart</i>	95
<i>Right atrium</i>	96
<i>Right ventricle</i>	97
<i>Left atrium</i>	98
<i>Left ventricle</i>	99

# CONTENTS

<i>Aortic valve and cardiac skeleton</i>	100	<i>Abdominal viscera</i>	153
<i>Cardiac chambers and heart valves</i>	101	<i>Peritoneal cavity</i>	154
<i>Coronary vessels</i>	102	<i>Abdominal sagittal section</i>	155
<i>Coronary arteries and variations</i>	103	<i>Abdominal coronal section</i>	156
<i>Cardiac conduction system</i>	105	<i>Arterial supply of viscera</i>	157
<i>Auscultation points and heart sounds</i>	106	<i>Stomach</i>	158
<i>Cardiac innervation</i>	107	<i>Spleen</i>	159
<i>Superior mediastinum: thymus</i>	108	<i>Arteries of stomach and spleen</i>	160
<i>Superior mediastinum: veins and arteries</i>	109	<i>Duodenum</i>	162
<i>Superior mediastinum: arteries and nerves</i>	110	<i>Small intestine</i>	164
<i>Superior mediastinum: imaging</i>	111	<i>Large intestine</i>	166
<i>Superior mediastinum: veins and trachea</i>	112	<i>Ileocecal junction</i>	168
<i>Mediastinum: imaging</i>	113	<i>Gastrointestinal tract: imaging</i>	169
<i>Mediastinum: view from right</i>	114	<i>Mesenteric arteries</i>	170
<i>Mediastinum: imaging – view from right</i>	115	<i>Liver</i>	172
<i>Mediastinum: view from left</i>	116	<i>Vessels of the liver</i>	174
<i>Mediastinum: imaging – view from left</i>	117	<i>Segments of the liver</i>	175
<i>Posterior mediastinum</i>	118	<i>Pancreas and gallbladder</i>	176
<i>Mediastinum: imaging</i>	120	<i>Vasculature of pancreas and duodenum</i>	179
<i>Transverse section: TVIII level</i>	124	<i>Venous drainage of viscera</i>	180
<i>Dermatomes and cutaneous nerves</i>	125	<i>Portosystemic anastomoses</i>	182
<i>Visceral efferent (motor) innervation of the heart</i>	126	<i>Posterior wall</i>	183
<i>Visceral afferents</i>	127	<i>Vessels of the posterior wall</i>	184
<i>Tables</i>	128	<i>Diaphragm</i>	185
		<i>Kidneys</i>	186
		<i>Gross structure of kidneys</i>	188
		<i>Kidneys: imaging</i>	189
		<i>Renal vasculature</i>	190
		<i>Branches of the abdominal aorta</i>	192
		<i>Inferior vena cava</i>	193
		<i>Abdominal aorta and inferior vena cava: imaging</i>	194
		<i>Lumbar plexus</i>	196
		<i>Lumbar plexus: cutaneous distribution</i>	197
		<i>Lymphatics</i>	198
		<i>Abdominal innervation</i>	199
		<i>Splanchnic nerves</i>	200
		<i>Visceral efferent (motor) innervation diagram</i>	201
		<i>Visceral afferent (sensory) innervation and referred pain diagram</i>	202
		<i>Kidney and ureter visceral afferent (sensory) diagram</i>	204
		<i>Tables</i>	206

## 4 ABDOMEN

<i>Surface anatomy</i>	134	<i>Branches of the abdominal aorta</i>	192
<i>Quadrants and regions</i>	135	<i>Inferior vena cava</i>	193
<i>Abdominal wall</i>	136	<i>Abdominal aorta and inferior vena cava: imaging</i>	194
<i>Muscles</i>	138	<i>Lumbar plexus</i>	196
<i>Muscles: rectus sheath</i>	141	<i>Lumbar plexus: cutaneous distribution</i>	197
<i>Vessels of the abdominal wall</i>	142	<i>Lymphatics</i>	198
<i>Arteries and lymphatics of the abdominal wall</i>	143	<i>Abdominal innervation</i>	199
<i>Nerves of the abdominal wall</i>	144	<i>Splanchnic nerves</i>	200
<i>Dermatomes and cutaneous nerves</i>	145	<i>Visceral efferent (motor) innervation diagram</i>	201
<i>Inguinal region</i>	146	<i>Visceral afferent (sensory) innervation and referred pain diagram</i>	202
<i>Inguinal canal</i>	148	<i>Kidney and ureter visceral afferent (sensory) diagram</i>	204
<i>Inguinal hernias</i>	150	<i>Tables</i>	206
<i>Anterior abdominal wall</i>	151		
<i>Greater omentum</i>	152		

**5 PELVIS AND PERINEUM**

<i>Surface anatomy and articulated pelvis in men</i>	212	<i>Deep pouch and perineal membrane</i>	259
<i>Surface anatomy and articulated pelvis in women</i>	214	<i>Muscles and erectile tissues in men</i>	260
<i>Pelvic girdle</i>	216	<i>Erectile tissue in men: imaging</i>	261
<i>Pelvic girdle: imaging</i>	217	<i>Muscles and erectile tissues in women</i>	262
<i>Lumbosacral joint</i>	218	<i>Erectile tissue in women: imaging</i>	263
<i>Sacro-iliac joint</i>	219	<i>Internal pudendal artery and vein</i>	264
<i>Pelvic inlet and outlet</i>	220	<i>Pudendal nerve</i>	265
<i>Orientation of pelvic girdle and pelvic brim</i>	221	<i>Vasculature of perineum</i>	266
<i>Pelvic viscera and perineum in men</i>	222	<i>Nerves of perineum</i>	267
<i>Pelvic viscera and perineum in men: imaging</i>	223	<i>Lymphatics of pelvis and perineum in men</i>	268
<i>Pelvic viscera and perineum in women</i>	224	<i>Lymphatics of pelvis and perineum in women</i>	269
<i>Pelvic viscera and perineum in women: imaging</i>	225	<i>Lymphatics</i>	270
<i>Lateral wall of pelvic cavity</i>	226	<i>Dermatomes</i>	271
<i>Floor of pelvic cavity: pelvic diaphragm</i>	227	<i>Innervation of reproductive system in men</i>	272
<i>Rectum and bladder in situ</i>	230	<i>Innervation of reproductive system in women</i>	273
<i>Rectum</i>	231	<i>Innervation of bladder</i>	274
<i>Bladder in men</i>	232	<i>Pelvic cavity imaging in men</i>	275
<i>Bladder in women</i>	233	<i>Pelvic cavity imaging in women</i>	278
<i>Reproductive system in men</i>	234	<i>Tables</i>	284
<i>Prostate</i>	235		
<i>Prostate and seminal vesicles</i>	237		
<i>Scrotum</i>	238		
<i>Testes</i>	239		
<i>Penis</i>	240		
<i>Reproductive system in women</i>	241		
<i>Uterus and ovaries</i>	242		
<i>Uterus</i>	243		
<i>Uterus: imaging</i>	244		
<i>Pelvic fascia</i>	245		
<i>Arterial supply of pelvis</i>	246		
<i>Venous drainage of pelvis</i>	247		
<i>Vasculature of the pelvic viscera</i>	248		
<i>Vasculature of uterus</i>	249		
<i>Venous drainage of prostate and penis</i>	250		
<i>Venous drainage of rectum</i>	251		
<i>Sacral and coccygeal nerve plexuses</i>	252		
<i>Pelvic nerve plexus</i>	253		
<i>Hypogastric plexus</i>	254		
<i>Surface anatomy of the perineum</i>	255		
<i>Borders and ceiling of the perineum</i>	258		

**6 LOWER LIMB**

<i>Surface anatomy</i>	292
<i>Bones of the lower limb</i>	293
<i>Pelvic bones and sacrum</i>	294
<i>Articulated pelvis</i>	295
<i>Proximal femur</i>	296
<i>Hip joint</i>	297
<i>Hip joint: structure and arterial supply</i>	299
<i>Gluteal region: attachments and superficial musculature</i>	300
<i>Gluteal region: superficial and deep muscles</i>	301
<i>Gluteal region: arteries and nerves</i>	302
<i>Distal femur and proximal tibia and fibula</i>	304
<i>Thigh: muscle attachments</i>	305
<i>Thigh: anterior superficial musculature</i>	306
<i>Thigh: posterior superficial musculature</i>	307
<i>Thigh: anterior compartment muscles</i>	308
<i>Thigh: medial compartment muscles</i>	309
<i>Femoral triangle</i>	310

# CONTENTS

<i>Anterior thigh: arteries and nerves</i>	311	<i>Posterior cutaneous nerves and dermatomes of</i>	
<i>Anterior thigh: arteries</i>	312	<i>the lower limb</i>	367
<i>Thigh: posterior compartment muscles</i>	313	Tables	368
<i>Posterior thigh: arteries and nerves</i>	314		
<i>Transverse sections: thigh</i>	316		
<i>Knee joint</i>	318		
<i>Ligaments of the knee</i>	320	<b>7 UPPER LIMB</b>	
<i>Menisci and cruciate ligaments</i>	322	<i>Surface anatomy</i>	384
<i>Knee: bursa and capsule</i>	326	<i>Bones of the upper limb</i>	385
<i>Knee surface: muscles, capsule, and arteries</i>	327	<i>Bony framework of shoulder</i>	386
<i>Popliteal fossa</i>	328	<i>Scapula</i>	387
<i>Tibia and fibula</i>	329	<i>Clavicle: joints and ligaments</i>	388
<i>Bones of the foot</i>	330	<i>Proximal humerus</i>	389
<i>Bones and joints of the foot</i>	333	<i>Glenohumeral joint</i>	390
<i>Talus and calcaneus</i>	334	<i>Muscle attachments</i>	392
<i>Ankle joint</i>	335	<i>Pectoral region</i>	394
<i>Ligaments of the ankle joint</i>	336	<i>Deep pectoral region</i>	395
<i>Leg: muscle attachments</i>	339	<i>Walls of the axilla</i>	396
<i>Posterior leg: superficial muscles</i>	340	<i>The four rotator cuff muscles</i>	398
<i>Posterior compartment: deep muscles</i>	341	<i>Deep vessels and nerves of the shoulder</i>	400
<i>Posterior leg: arteries and nerves</i>	342	<i>Axillary artery</i>	401
<i>Lateral compartment: muscles</i>	343	<i>Brachial artery</i>	402
<i>Anterior leg: superficial muscles</i>	344	<i>Brachial plexus</i>	403
<i>Anterior compartment: muscles</i>	345	<i>Medial and lateral cords</i>	404
<i>Anterior leg: arteries and nerves</i>	346	<i>Posterior cord</i>	405
<i>Leg: cutaneous nerves</i>	347	<i>Distal end of humerus and proximal end</i>	
<i>Transverse sections: leg</i>	348	<i>of radius and ulna</i>	406
<i>Foot: muscle attachments</i>	350	<i>Muscle attachments</i>	407
<i>Foot: ligaments</i>	351	<i>Anterior compartment: muscles</i>	408
<i>Dorsum of foot</i>	353	<i>Anterior compartment: arteries and nerves</i>	410
<i>Dorsum of foot: arteries and nerves</i>	354	<i>Veins of the arm</i>	411
<i>Plantar aponeurosis</i>	356	<i>Posterior compartment: muscles</i>	412
<i>Plantar region (sole) musculature: first layer</i>	357	<i>Posterior compartment: arteries and nerves</i>	414
<i>Plantar region (sole) musculature: second layer</i>	358	<i>Lymphatics of the arm</i>	415
<i>Plantar region (sole) musculature: third layer</i>	359	<i>Transverse sections: arm</i>	416
<i>Plantar region (sole) musculature: fourth layer</i>	360	<i>Anterior cutaneous nerves of the arm</i>	418
<i>Plantar region (sole): arteries and nerves</i>	361	<i>Posterior cutaneous nerves of the arm</i>	419
<i>Dorsal hood and tarsal tunnel</i>	363	<i>Elbow joint</i>	420
<i>Superficial veins of the lower limb</i>	364	<i>Elbow joint: capsule and ligaments</i>	422
<i>Lymphatics of the lower limb</i>	365	<i>Cubital fossa</i>	424
<i>Anterior cutaneous nerves and dermatomes of</i>		<i>Radius and ulna</i>	425
<i>the lower limb</i>	366	<i>Bones of the hand and wrist joint</i>	426

<i>Imaging of the hand and wrist joint</i>	427	<i>Maxilla and palatine bone</i>	487
<i>Bones of the hand</i>	428	<i>Skull: muscle attachments</i>	488
<i>Joints and ligaments of the hand</i>	429	<i>Scalp and meninges</i>	490
<i>Muscle attachments of forearm</i>	430	<i>Dural partitions</i>	491
<i>Anterior compartment of forearm: muscles</i>	431	<i>Dural arteries and nerves</i>	492
<i>Anterior compartment of forearm:</i>		<i>Dural venous sinuses</i>	493
<i>arteries and nerves</i>	434	<i>Brain</i>	494
<i>Posterior compartment of forearm: muscles</i>	435	<i>Brain: imaging</i>	496
<i>Posterior compartment of forearm:</i>		<i>Cranial nerves</i>	498
<i>arteries and nerves</i>	437	<i>Arterial supply to brain</i>	500
<i>Transverse sections: forearm</i>	438	<i>Cutaneous distribution of trigeminal nerve [V]</i>	503
<i>Carpal tunnel</i>	440	<i>Facial muscles</i>	504
<i>Muscle attachments of the hand</i>	442	<i>Vasculature, facial nerve [VII] and lymphatics</i>	506
<i>Superficial palmar region (palm) of hand</i>	443	<i>Deep arteries and veins of parotid region</i>	507
<i>Tendon sheaths of hand</i>	444	<i>Bony orbit</i>	508
<i>Lumbrical muscles</i>	445	<i>Section through orbit and structures of eyelid</i>	509
<i>Intrinsic muscles of hand</i>	446	<i>Eyelids and lacrimal apparatus</i>	510
<i>Palmar region (palm) of hand: arteries and nerves</i>	448	<i>Innervation of the lacrimal gland</i>	511
<i>Arteries of the hand</i>	450	<i>Muscles of the eyeball</i>	512
<i>Innervation of the hand: median and ulnar nerves</i>	451	<i>Innervation of the orbit and eyeball</i>	513
<i>Dorsum of hand</i>	452	<i>Eye movements</i>	514
<i>Dorsal hoods</i>	453	<i>Vasculature of orbit</i>	515
<i>Dorsum of hand: arteries</i>	454	<i>Eyeball</i>	516
<i>Dorsum of hand: nerves</i>	455	<i>Eye imaging</i>	517
<i>Anatomical snuffbox</i>	456	<i>Ear surface and sensory innervation</i>	520
<i>Superficial veins and lymphatics of forearm</i>	457	<i>Ear</i>	521
<i>Anterior cutaneous nerves of forearm</i>	458	<i>Middle ear</i>	522
<i>Posterior cutaneous nerves of upper limb</i>	459	<i>Internal ear</i>	524
<i>Tables</i>	460	<i>Ear imaging</i>	525
		<i>Temporal and infratemporal fossae</i>	526
		<i>Bones of the temporal and infratemporal fossae</i>	527
		<i>Temporal and infratemporal fossae</i>	528
		<i>Temporomandibular joint</i>	530
		<i>Mandibular division of the trigeminal nerve [V]</i>	531
		<i>Parasympathetic innervation</i>	532
		<i>Arteries and veins of temporal and</i>	
		<i>infratemporal fossae</i>	533
		<i>Pterygopalatine fossa</i>	534
		<i>Neck surface anatomy</i>	536
		<i>Bones of the neck</i>	537
		<i>Compartments and fascia of the neck</i>	538
		<i>Superficial veins of the neck</i>	539

## 8 HEAD AND NECK

<i>Surface anatomy with bones</i>	476		
<i>Bones of the skull</i>	477		
<i>Skull: anterior view</i>	478		
<i>Skull: lateral view</i>	480		
<i>Skull: posterior view</i>	482		
<i>Skull: superior view and roof</i>	483		
<i>Skull: inferior view</i>	484		
<i>Skull: cranial cavity</i>	485		
<i>Ethmoid, lacrimal bone, inferior concha, and vomer</i>	486		

# CONTENTS

<i>Muscles of the neck</i>	<i>540</i>	<i>Nasal cavity: mucosal linings</i>	<i>568</i>
<i>Nerves in the neck</i>	<i>542</i>	<i>Vasculature and innervation of the nasal cavity</i>	<i>569</i>
<i>Cranial nerves in the neck</i>	<i>543</i>	<i>Sinus imaging</i>	<i>570</i>
<i>Cervical plexus and sympathetic trunk</i>	<i>544</i>	<i>Oral cavity: bones</i>	<i>572</i>
<i>Arteries of the neck</i>	<i>546</i>	<i>Teeth</i>	<i>573</i>
<i>Root of the neck: arteries</i>	<i>548</i>	<i>Teeth: imaging</i>	<i>574</i>
<i>Lymphatics of the neck</i>	<i>550</i>	<i>Anatomy of teeth</i>	<i>575</i>
<i>Pharynx</i>	<i>552</i>	<i>Vessels and nerves supplying teeth</i>	<i>576</i>
<i>Muscles of the pharynx</i>	<i>554</i>	<i>Innervation of teeth and gums</i>	<i>577</i>
<i>Innervation of the pharynx</i>	<i>556</i>	<i>Muscles and salivary glands of the oral cavity</i>	<i>578</i>
<i>Vasculature of the pharynx</i>	<i>557</i>	<i>Vessels and nerves of the tongue</i>	<i>579</i>
<i>Larynx</i>	<i>558</i>	<i>Tongue</i>	<i>580</i>
<i>Laryngeal cavity</i>	<i>560</i>	<i>Hard and soft palate</i>	<i>581</i>
<i>Muscles of the larynx</i>	<i>561</i>	<i>Palate</i>	<i>582</i>
<i>Innervation of the larynx</i>	<i>562</i>	<i>Innervation of oral cavity</i>	<i>583</i>
<i>Thyroid gland</i>	<i>563</i>	<i>Cranial nerves</i>	<i>584</i>
<i>Vasculature of the thyroid gland</i>	<i>564</i>	<i>Visceral motor pathways in the head</i>	<i>586</i>
<i>Nose and paranasal sinuses</i>	<i>566</i>	<i>Tables</i>	<i>588</i>
<i>Nasal cavity: bones</i>	<i>567</i>		
		<i>INDEX</i>	<i>609</i>